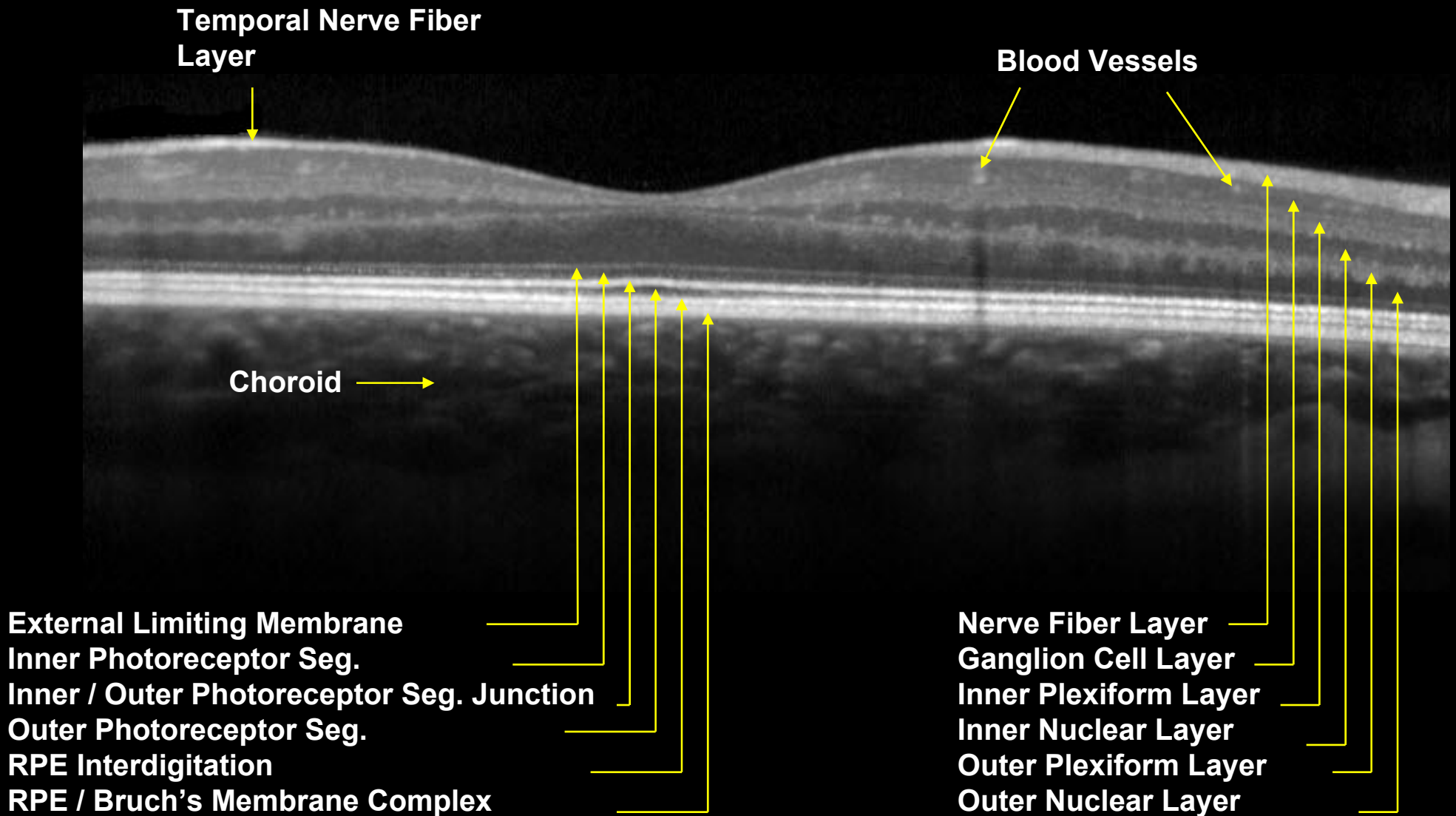


# Spectralis - Retinal Layers (Normal)



# Spectralis - Optic Nerve (Parapapillary Atrophy)

